



PRESENTING CLINICAL SIGNS

DATE History: Grade 1/6 murmur. PU/PD, pot belly appearance. BNP WNL.

ECHOCARDIOGRAPHIC FINDINGS

4/28/22 2D, M-mode, and Doppler study.

PERFORMED BY:

Rebekah Jakum

INTERPRETED BY

Keith Blass, DVM,
MS, DACVIM
(Cardiology)

Left atrial size is normal. The mitral valve appears normal, though trace mitral regurgitation is present. Left ventricular dimensions are normal. Left ventricular systolic function is normal. The aorta and aortic valve are normal. Right atrial and right ventricular dimensions are normal. The tricuspid valve leaflets are mildly thickened, and a mild jet of tricuspid regurgitation is present. TR velocity does not suggest the presence of pulmonary hypertension. The pulmonary artery and pulmonic valve are normal. No pericardial effusion or cardiac masses are seen.

PATIENT

Joeyvanna
Pietkiewicz

LA - 26.3 mm
LVIDd - 22.2 mm
LVIDs - 13.1 mm
FS - 41%
RA - 18.8 mm
LVOT - 1.60 m/s
RVOT - 1.05 m/s
TR - 2.15 m/s

ASSESSMENT/RECOMMENDATIONS

SPECIES Degenerative tricuspid valve disease

Canine

BREED

Dachshund

This examination demonstrates mild regurgitation of blood across Joeyvanna's tricuspid valve resulting from degenerative valve disease. The hemodynamic effects of the regurgitation also appear to be mild, as Joeyvanna does not have secondary dilation of either of his right heart chambers. As such, Joeyvanna's tricuspid valve disease appears to be well-compensated, and it does not appear to be the cause of his pot-bellied appearance.

No therapy is recommended at this stage of disease.

SEX

A recheck echocardiogram is recommended in ~9 months, sooner if new clinical signs compatible with cardiac dysfunction develop.

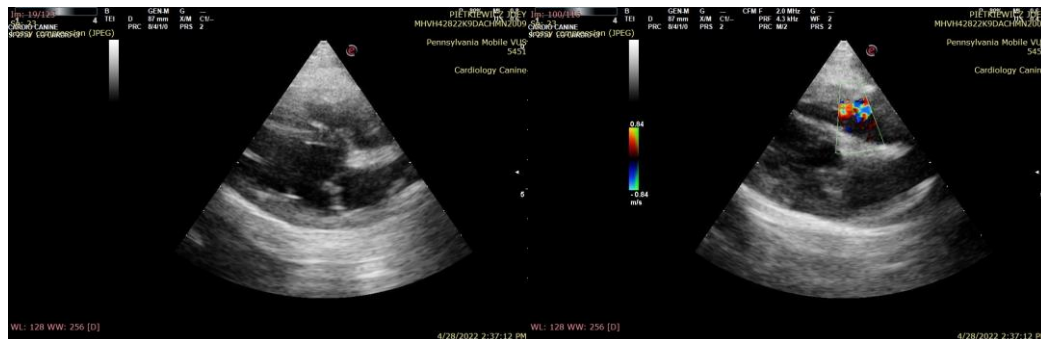MN

AGE

13 y

WEIGHT

17.7 lb



HOSPITAL NAME

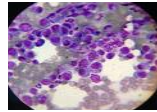
Maple Hills VH

The information and recommendations provided are based on the images presented by the referring veterinarian. No evaluation can be communicated regarding pathology that was not visible in the image/video clips provided.

REFERRING VET

Dr. Banzhof

Thank you for this referral. If the clinical or image interpretation does not parallel your findings or if I can be of any further assistance please contact me.



DATE

4/28/22

Keith Blass, DVM, MS, DACVIM (Cardiology)
KeithBlass@gmail.com
631-804-5754

PERFORMED BY:

Rebekah Jakum

INTERPRETED BY

Keith Blass, DVM,
MS, DACVIM
(Cardiology)

PATIENT

Joeyvanna
Pietkiewicz

SPECIES

Canine

BREED

Dachshund

SEX

MN

AGE

13 y

WEIGHT

17.7 lb

HOSPITAL NAME

Maple Hills VH

REFERRING VET

Dr. Banzhof